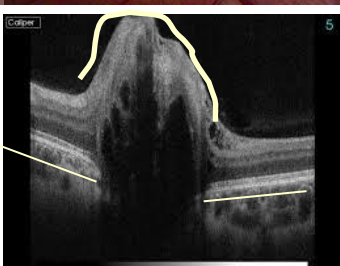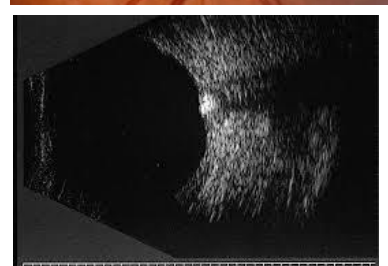
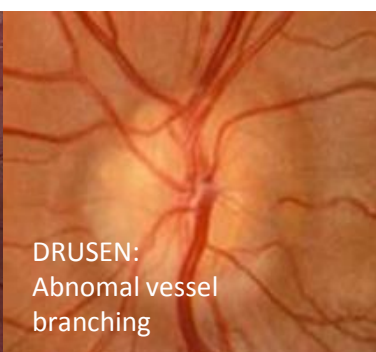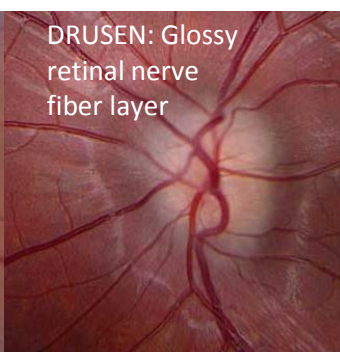
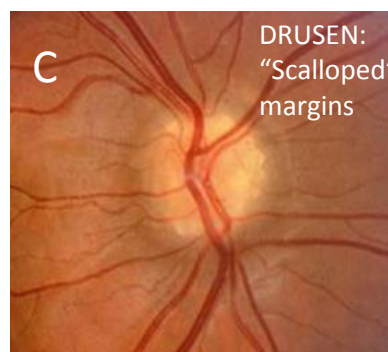
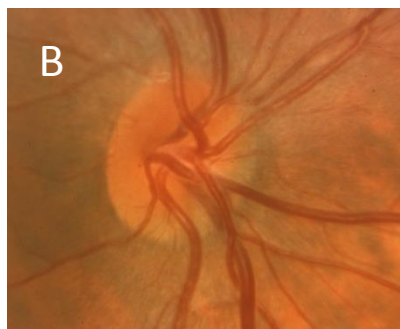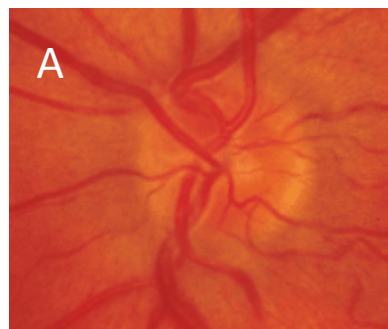
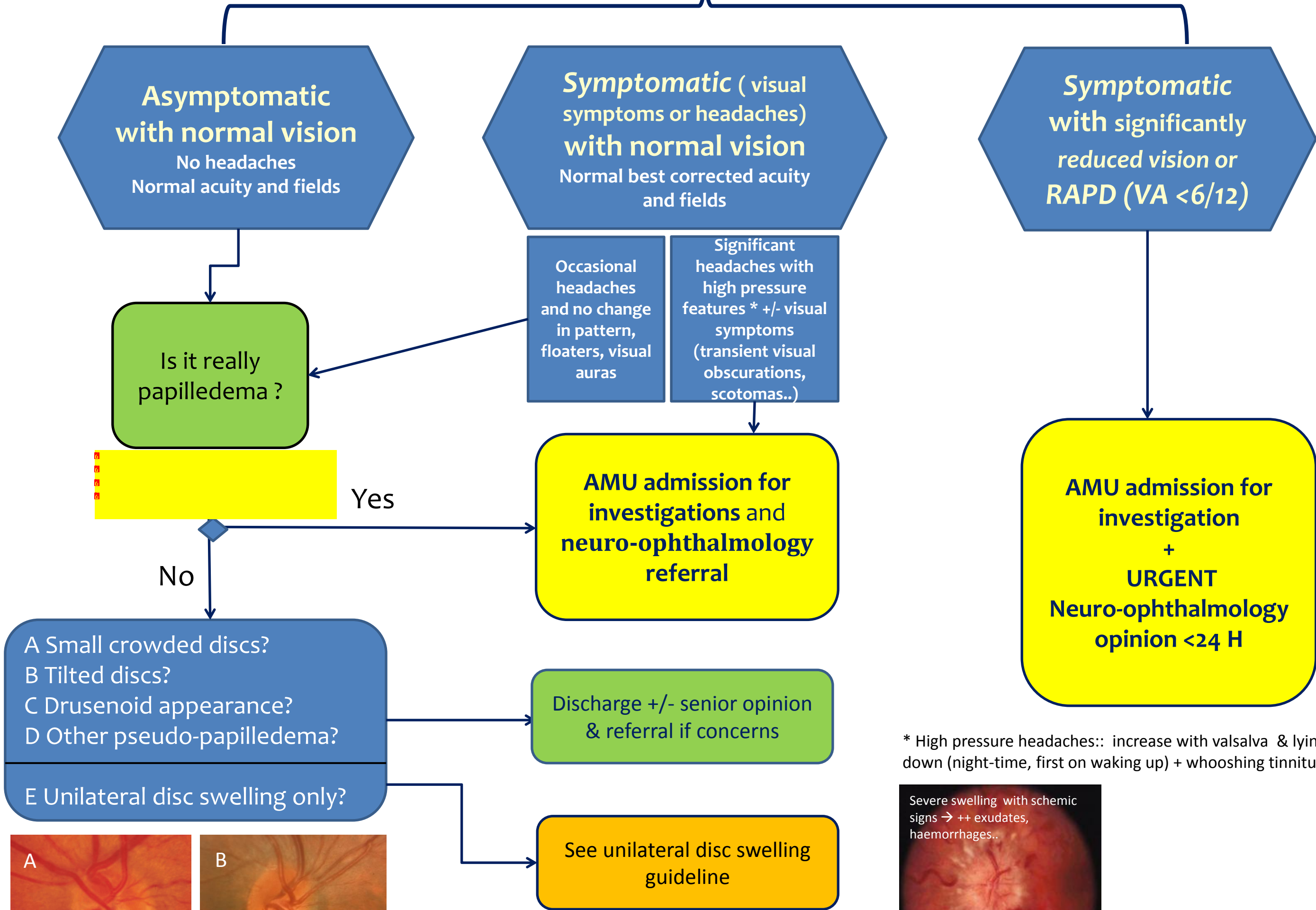
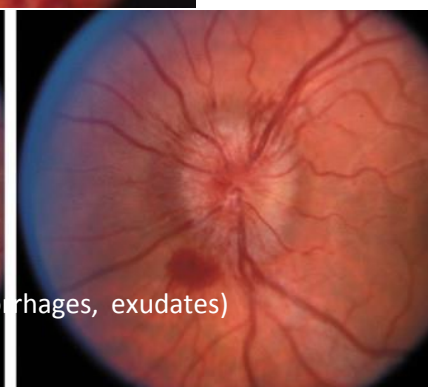
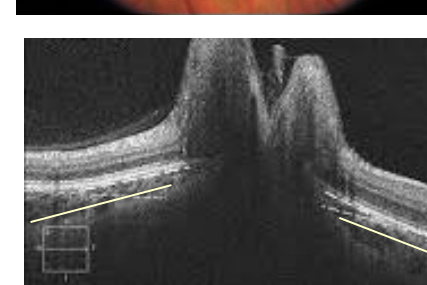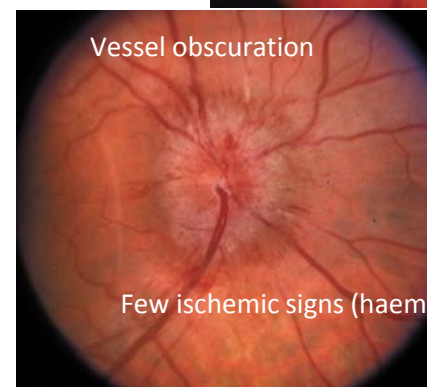
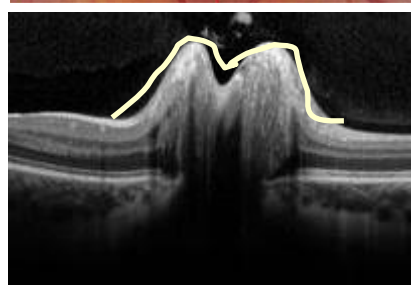
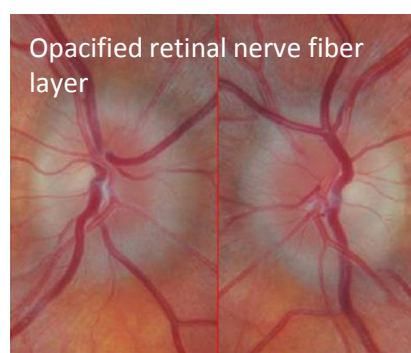


Bilateral optic nerve swelling

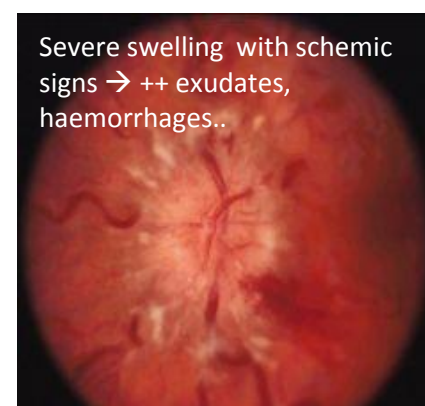
- Complete medical & system history & visual function ✓
- Most senior doctor in casualty to assess discs and history ✓
- Blood pressure → (exclude malignant hypertension) ✓
- Disc photos or OCT optic nerve fiber layer: Document appearance at presentation as accurately as possible ✓



DRUSEN: hyper-reflective nodules within the optic nerve
DRUSEN: Maximal elevation on OCT usually central, angulation of Bruch's membrane towards the sclera (or flat)



* High pressure headaches: increase with Valsalva & lying down (night-time, first on waking up) + whooshing tinnitus



PAPILLEDEMA: OCT is of limited diagnostic use: always correlate with funduscopy. Doughnut elevation with central dip. Angulation of Bruch's membrane towards the retina ("inwards"); note this last sign usually is seen when papilledema is clinically evident / florid. Invest Ophthalmol Vis Sci 2011